

A MODIFIED METHOD OF MICROVASCULAR AUTOGENOUS INTERPOSITION VEIN GRAFTING FOR VASCULAR RECONSTRUCTION

Fatih PARMAKSIZOGLU¹, Tahsin BEYZADEOGLU²

¹Yeditepe University, School of Medicine, Department of Orthopedics and Traumatology Istanbul - TURKEY

²Private Umut Hospital, Department of Orthopedics and Traumatology, Istanbul – TURKEY

The most frequently encountered problems during vein grafting are diameter, length discrepancies and twisting of the anastomosed vein and recipient vessel.

Diameter of the graft: After performing an anastomosis, under high pressure, the widening of the graft's diameter leads turbulence of the blood flow. The diameter and size mismatch of the vein grafts is prone to thrombus formation and subsequent graft failure.(Figure 1)

Length of the grafts: However the length of the vein graft did not alter the degree of the patency the determination of the length of the graft is difficult because of retraction of the recipient vessel ends and elongation of the graft itself. Vein grafts always elongate after reperfusion. Considerable experience is required for the determination of the length of the vein graft to bridge the defect. If the graft is harvested too short, tension over the anastomosis site occurs; if the graft is too long, recovery of the arterial ends' retraction and elongation of the graft under pressure cause kinking. A graft equal in length to the vascular gap will be too long after it is elongated by the blood pressure. Experimentally, the graft can be up to 35 percent longer than the replaced segment without kinking. Some techniques to prevent these difficulties have been presented. The graft should be just shorter than the length of the gap and should be sutured under slight tension and double - clamp anastomosis can be performed. The clamps are left in place, proximally and distally. After the completion of both anastomoses, the distal one is released first. Measuring the graft in situ or completing the proximal anastomosis first and allowing the blood to fill the graft are the techniques that can be used to assume the natural length of the graft, but re-shortening the graft or re-anastomosing are the technical difficulties and time-wasting procedures.(Figure 2)

Twisting and torsion of the graft: Especially twisting and torsion of the graft may be a major problem in long grafts tunneled under closed sites. During the anastomosis, a very unremarkable torsion over the anastomosis site may be a reason of kinking and twisting of the graft. This neglected torsion effect combines on one point causing obstruction, when it goes under pressure. A method to prevent twisting is allowing the vein graft to perfuse with arterial blood for a short period transiently so that it will unwind and extend to its full length and performing the distal anastomosis later, but thrombosis of the graft is possible despite heparinized saline perfusion because of the stasis of the arterial blood. Sometimes a catheterization just proximal than the proximal anastomosis is needed for heparinized saline wash. "Loop technique" is another solution to avoid twisting of long grafts, especially in free tissue transfers.(Figure 3)

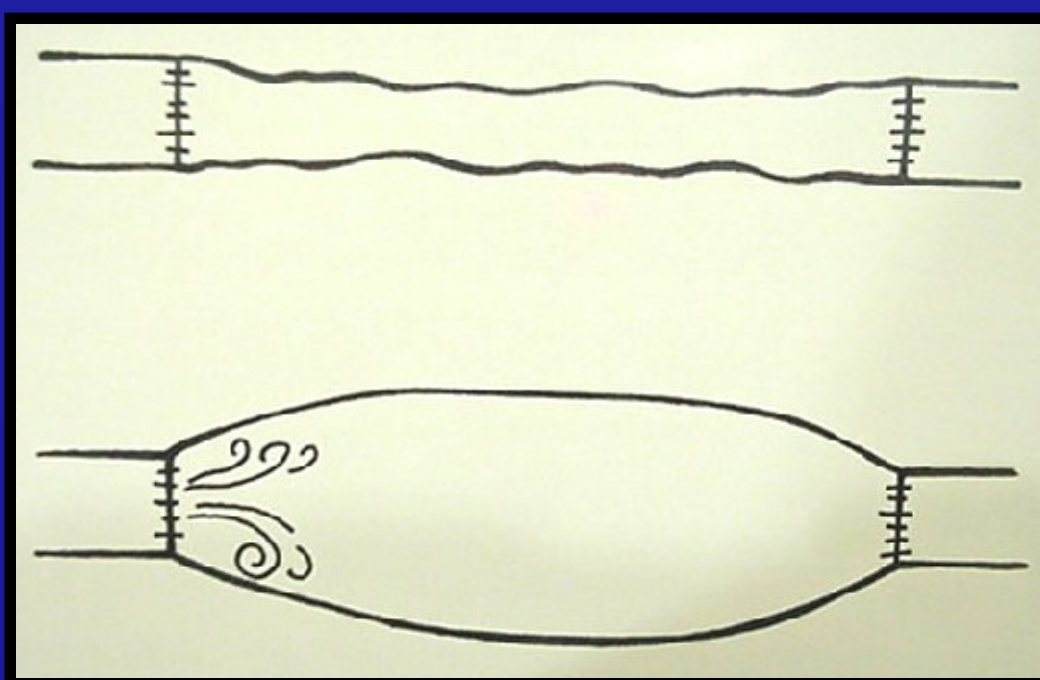


Figure 1




Figure 2




Figure 3

In our clinic, we have performed a simple method for vein grafting that eliminates many of the technical difficulties and time-wasting procedures.

MATERIALS AND METHODS:

The vein graft is harvested 20 percent *longer* than the vascular gap. Determining the valves, *the distal end is ligated* and the graft is washed with heparinized saline. The graft is inflated with the saline until the spasm along the vein is relieved and adequate dilation for arterial blood pressure is obtained. The gentle hydrostatic dilation straightens out the vein, relieves spasms, makes division of the adventitial constriction bands easier and identifies leaks so that the small side branches become more visible to be ligated. The *proximal site of the graft is ligated* while it is *filled* with the heparinized saline *under adequate pressure*. Now the vein graft has its maximum size, diameter and length while it is filled with saline and both of the anastomoses sites and side branches are ligated. (Figure 4-5)

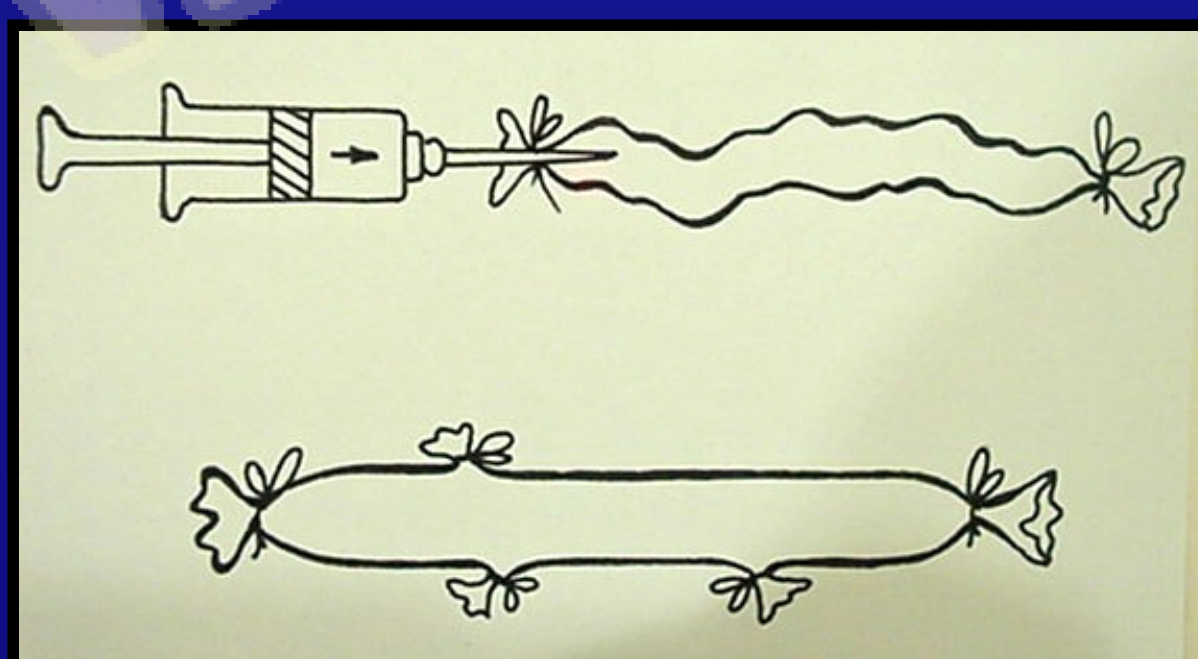


Figure 4

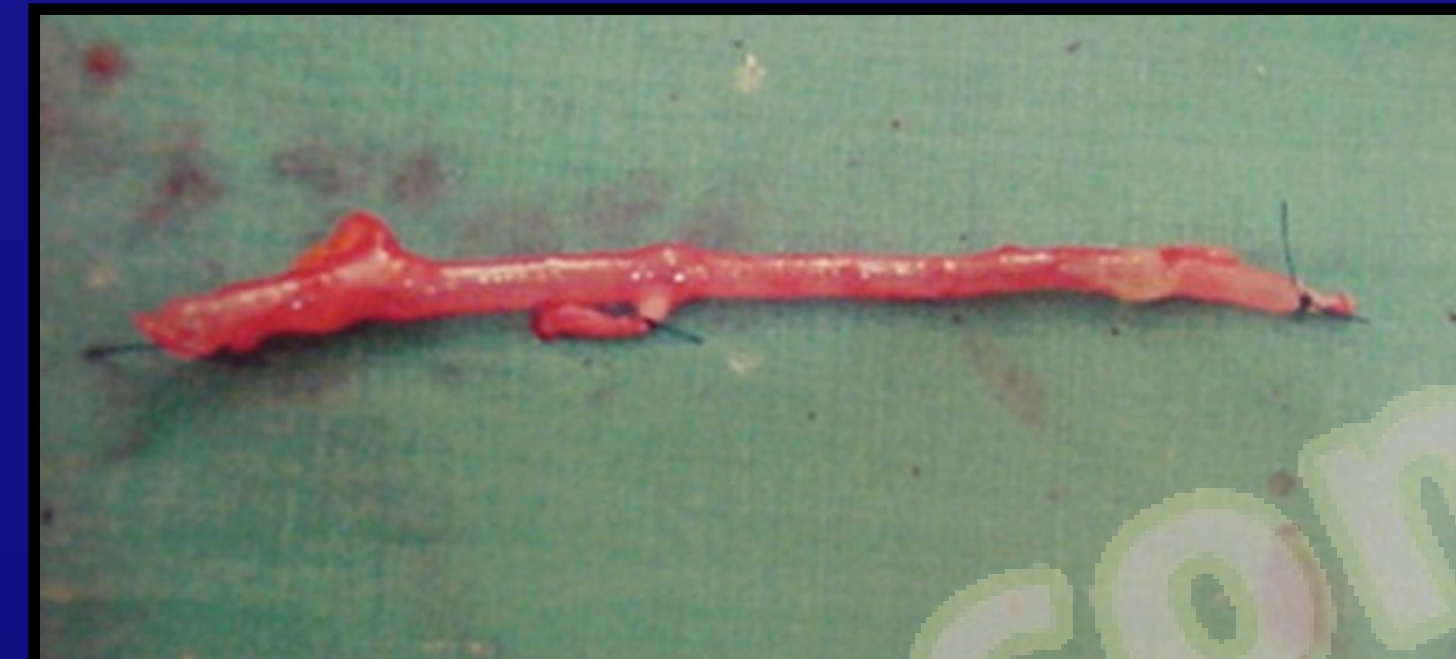

Figure 5

After the resection of adventitial constriction bands, this sausage-like graft can be easily *interposed under tunnels, passages or soft tissues* between the recipient vessel gaps. As the graft is under tension, it will not be difficult to determine the appropriate length and it can be shortened just equal to the gap length. As the length of the harvested graft can easily be modified by this technique, length discrepancies will not occur. The graft is shortened in adequate length. This length will be equal to the gap while the graft is still under pressure and filled with the solution. The graft also has no chance to twist, as it will be interposed under tension. The suturing is carried out with *double approximator clamps*. The clamps are left in place until completion of distal and proximal anastomoses respectively. The distal one is released first. (Figure 6-7-8)

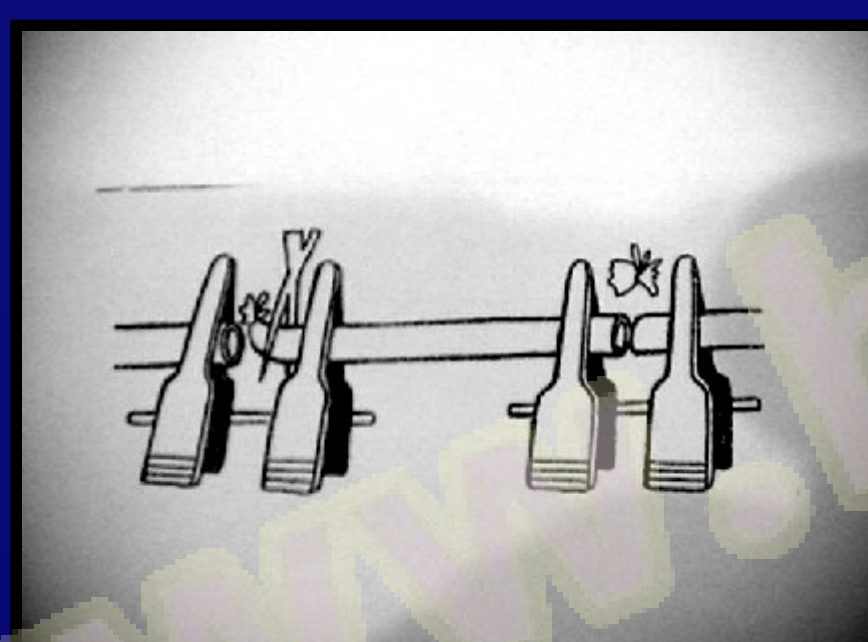


Figure 6

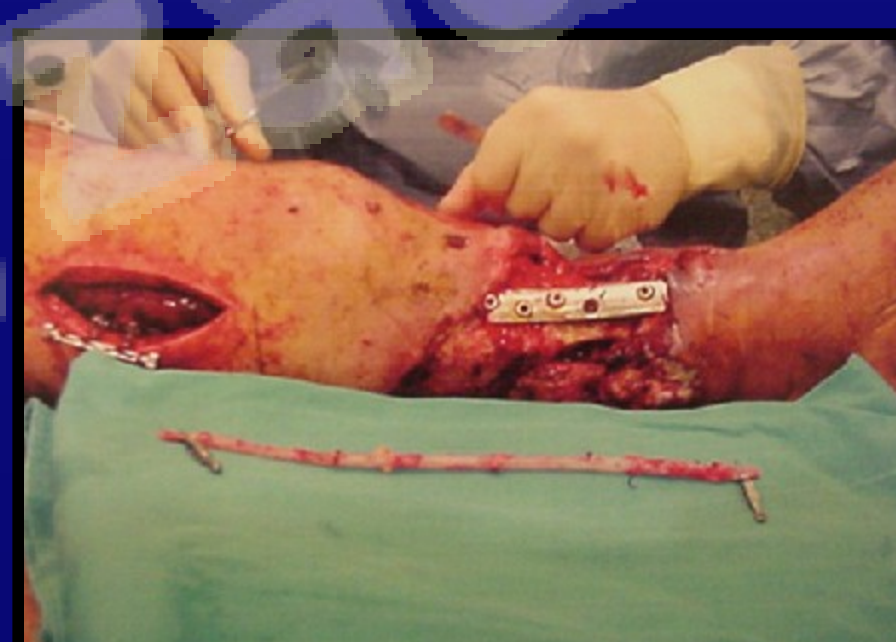

Figure 7

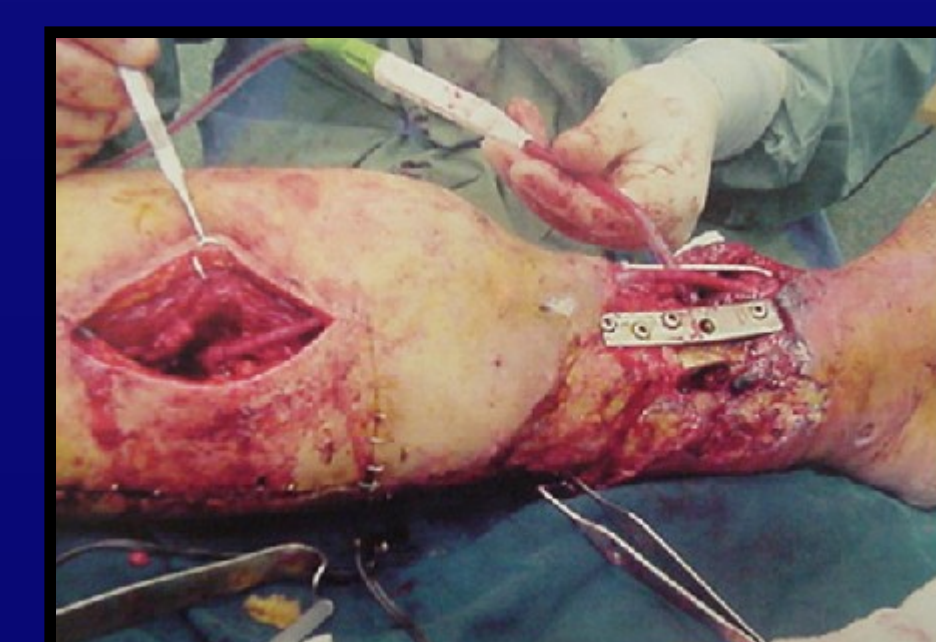


Figure 8

CONCLUSION:

In the meantime, autogenous vein grafting for vascular reconstruction is a well defined and widely used technique, but still considerable problems in practice are encountered. By this simple method, most of the technical difficulties like length determination, size and diameter discrepancies, twisting and torsion of the graft can be eliminated. Failure risk due to vascular thrombosis at the anastomotic sites is lowered as the vein graft is filled with heparinized saline and no blood flow is permitted during the reconstruction. The surgeon also saves time by this easy, simple, feasible method.