

# COMPOSITE OSTEOCUTANEOUS GROIN FLAP COMBINED WITH NEUROVASCULAR ISLAND FLAP FOR THUMB RECONSTRUCTION

Fatih PARMAKSIZOGLU<sup>1</sup>, Tahsin BEYZADEOGLU<sup>2</sup>

<sup>1</sup>Yeditepe University, School of Medicine, Department of Orthopedics and Traumatology Istanbul - TURKEY

<sup>2</sup>Private Umut Hospital, Department of Orthopedics and Traumatology, Istanbul – TURKEY

Thumb reconstruction should be considered in the traumatic loss of this digit as it causes significant functional disability, constituting approximately 40 - 50 % of the total function of the hand. The CMC joint is the organizer of the thumb. The ideal condition for a functional thumb reconstruction is intact and actively controlled CMC joint and first metacarpal. Many reconstruction techniques like toe to thumb transfer with or without bone grafting, lengthening of the first metacarpal with or without web deepening and pollicization with the other digits have been reported for the levels between proximal to MCP and IP joints. We report the results of composite osteocutaneous groin flap combined with neurovascular island flap with reduced complications due to non-vascularized bone grafts and morbidity of the donor site in three cases of thumb reconstruction.

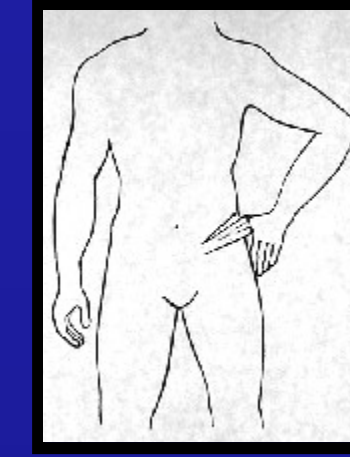
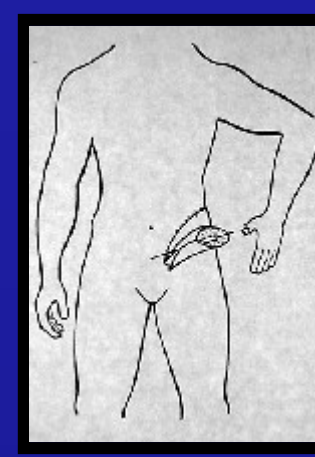
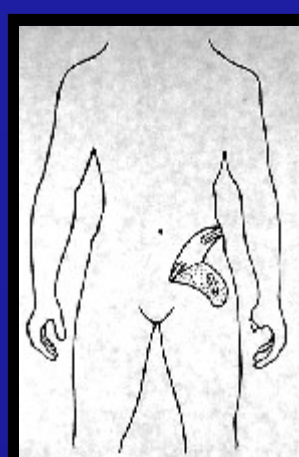
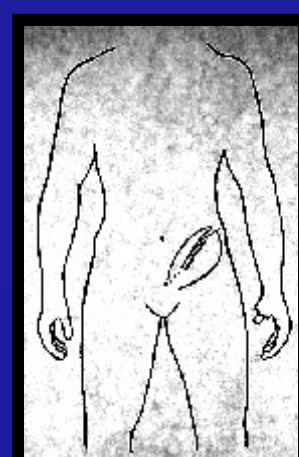
## PATIENTS AND METHODS:

### Study cases

Three amputated thumbs were reconstructed with a composite osteocutaneous groin flap combined with neurovascular island flap. Two of the patients were male and one was female. The average age at the time of surgery was 28.3 years (range, 25-35 years). Two of the injured thumbs were left sided, while one was right. The level of the amputation was distal to MCP joint in two cases and proximal in one case. The injury mechanism was avulsion in all of the cases. One of the cases has to be reconstructed after the failure of primary replantation. The postoperative follow-up periods ranged from 27 to 30 months (mean, 28.3 months).

### Operative Technique

Preparing the groin tubed pedicle flap: A groin flap was designed and elevated along the axis between pubis and anterior superior iliac spine over the iliac crest ipsilateral to the injured thumb. The tricortical bone block segment from the iliac crest was elevated from just distal to the anterior superior iliac spine, taking care not to detach it from the skin, subcutaneous tissue and fascia. The length of the tricortical iliac bone was 8-cm. in length and 2-cm. in height to safe the vascularization of the bone block considering the remodeling chance in the future. The bone block and the stump were fixated securely by two crossing K-wires in two cases and one K-wire in one case that were inserted retrogradly through the vascularized iliac tricortical bone block. Then the flap was made into a tube that was sutured to the base of the thumb. All wounds healed per primam. After 4 weeks, the composite flap was cut free from groin under local anesthesia and the donor area was closed primarily. Shortening or remodelling of the flap was carried out to shape the thumb referring the comparison x-rays of the opposite thumb, after the bony consolidation.

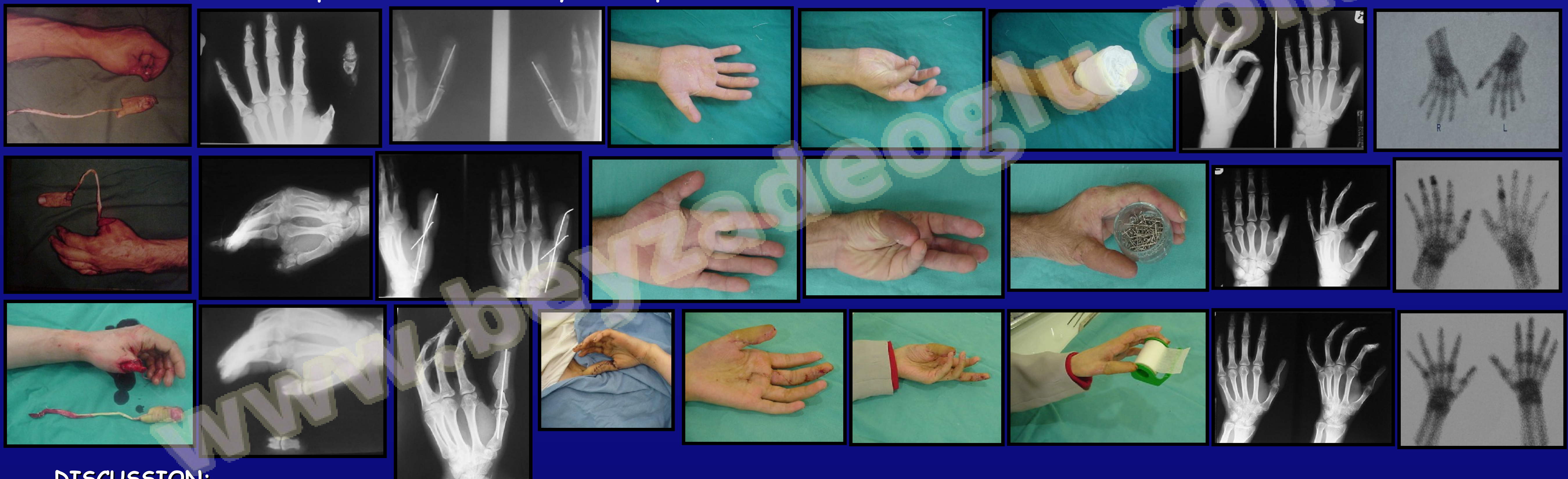

## Neurovascular Island Flap:

NVIF procedure was completed 3 weeks after the bone remodelling in the third surgery. A flap from the ulnar side of the middle finger was obtained for covering the distal pinching area of the volar region.

## RESULTS:

There was no limitation in opposition of the thumb tip to the fingers and all of the three patients were capable of functional motion including pinch as well as grasp and grip. All of the cases had sensation to temperature variations, touch, static and moving two point discriminations. Sensory switching had also recovered. The vascularization and the healing of the bone were evaluated with periodic x-rays and with 3-phased scintigraphy that was performed at the second year follow-up in all of the patients. The evaluation of the x-rays and 3-phased-scintigraphy demonstrated excellent union of the iliac bone block and the stump without any resorption. We have not encountered skin necrosis, bone resorption or infection in any of the patients.



## DISCUSSION:

Most of the thumb injuries are in crush or avulsion type and inappropriate cases for primary replantation or revascularization. The preferred method for thumb reconstruction depends to the surgeon with alternatives of toe transfer, pollicization, metacarpal lengthening, bone grafting with wraparound free flap. Resorption or non-union of the graft; infection with or without bone sequestrization, fracture of the graft because of the osteoporosis are frequently encountered complications. Donor site morbidity should not also be underestimated. Our first choice for thumb reconstruction is microsurgical techniques, however it may sometimes be difficult to convince the patient to sacrifice another of his digits. We have performed three cases of composite osteocutaneous groin flap with neurovascular island flap for thumb reconstruction and followed the cases for more than two years. At the end of this follow-up period, we have decided to prefer this method in inappropriate cases for other ways of thumb reconstruction, as it especially prevents complications due to bone resorption. The uninterrupted blood supply to the bone gives up rapid healing by speeding bone-to-bone union and stability without any resorption, as the vascularized bone has never been completely detached from an intact nutrient blood supply from the overlying soft tissue. The surgical procedure was noticeably more reliable and simpler from the other reconstruction methods and the functional results were satisfying. The only major disadvantage that we have observed was aesthetical due to absence of the nail. We have concluded that groin flap with a vascularized iliac bone has to be considered as a good treatment modality choice for thumb reconstruction.