

**THE TREATMENT OF AVULSION
TYPE OF FINGER AMPUTATIONS:
IMPORTANCE OF ARTERIAL
BRANCHES FOR DETERMINING THE
SUITABLE PART OF THE VESSEL**

Fatih PARMAKSIZOGLU¹, Tahsin BEYZADEOGLU²

¹Yeditepe University, Faculty of Medicine,
Department of Orthopaedics and Traumatology

²Private Umut Hospital, Department of Orthopaedics and Traumatology
Istanbul - TURKEY

Vascular Damage

- **Extensive** vascular damage occurs in avulsion type of injuries after the skeletal support is removed by fracture or disarticulation.
- It is important to **recognize** and **resect** the **damaged** parts of the arteries for a successful revascularization.

Treatment Options

- After radical vascular resection,
 - primary anastomosis with shortening of the bone,
 - limited bone shortening with vein grafting,
 - transposition of the neighbour digital artery can be achieved.

How much vascular resection?

- To determine the suitability of the vessels for anastomosis:
 - **Ribbon Sign**
 - **Side Branches****can be used as indirect methods.**

www.beyzadeoglu.com

Ribbon Sign

- In 1978; Van Beek et al. reported the importance of Ribbon Sign for determining the suitability of the vessel for anastomosis.

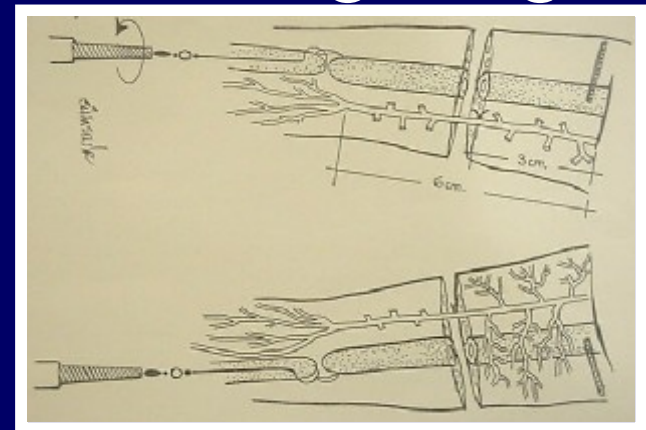
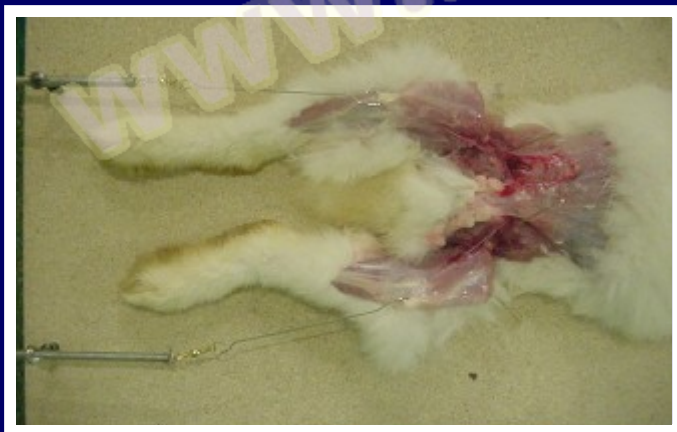
www.beyzadoglu.com

Side Branches

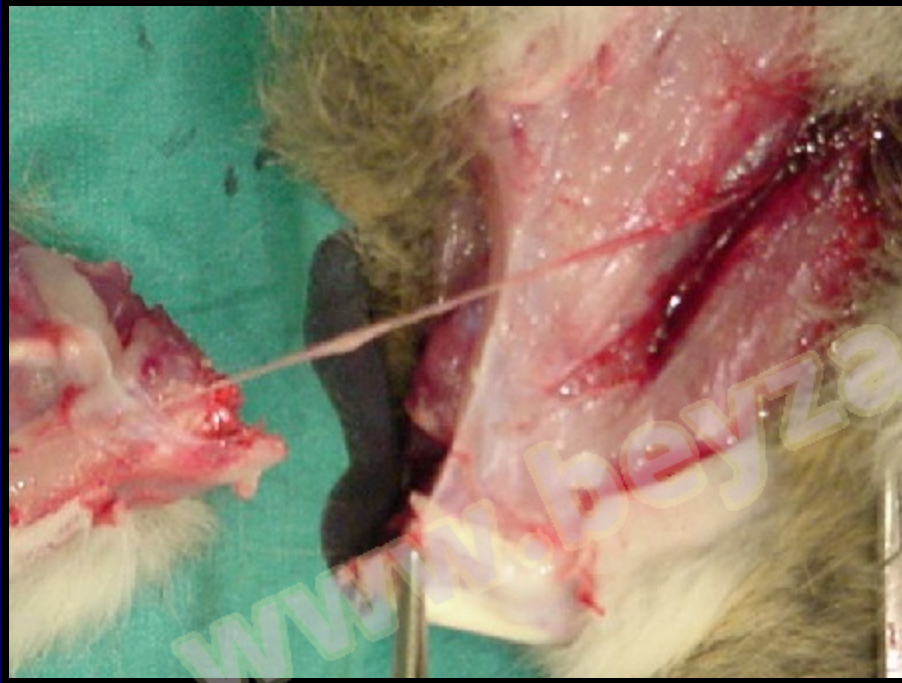- Good forward flow from the proximal artery after resecting past a side branch point was reported by Mitchell et al. in 1985. (but without any comment, as only personal observation).
- We tried to show the effect of side branches in stretching of the parent trunk with emphasis on preventing the *mechanic* and *metrical* effect of avulsion, experimentally.

Experiment

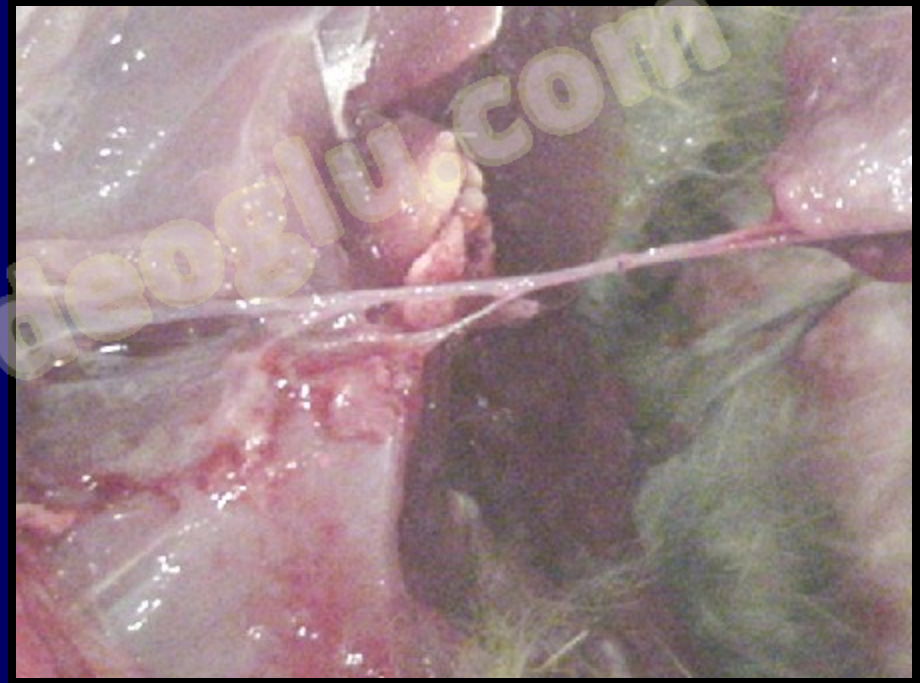- An operation and traction system was prepared to employ a *controlled longitudinal traction* to femoral arteries of rabbits to create an avulsion type of injury.
- The side branches of the femoral artery were protected at the left legs while all of the side branches were ligated and cut at the right legs.



If the main damage mechanism of the avulsion injury is the stretching of the arteries and resulting intimal tears...

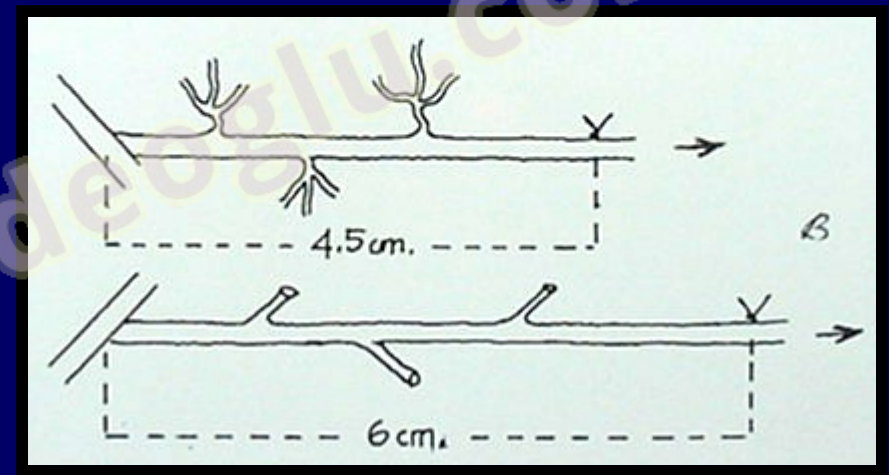
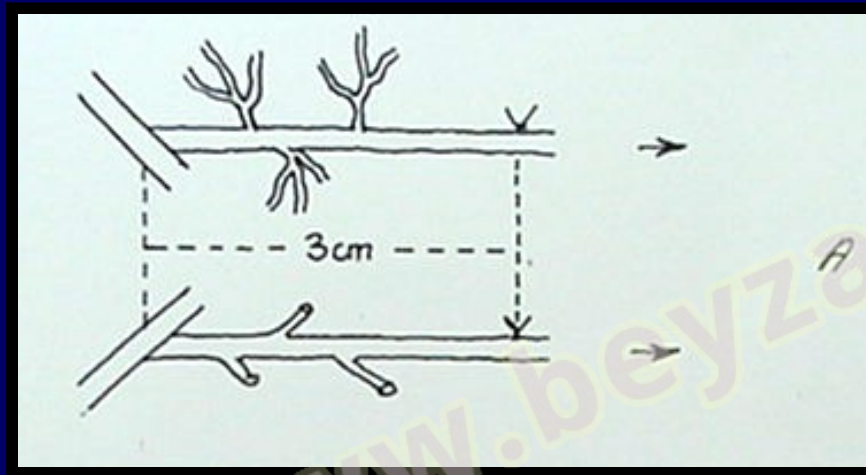


The arteries without side branches at the right legs were lengthening more as they do not have any fixating and protective support such as side branches.



Tethering of the side branches at the left legs was preventing the elongation of the parent trunk.

Elongation of the arteries just before the avulsion at each side with and without side branches was compared by the initial and last measurements of the same distances...



An average of 50% more elongation was measured at the legs without side branches concluding a possible severe injury of the artery.

- In the view of these results; for *primary anastomosis*, we suggest performing microsurgical anastomosis after resection past a minimum of two *unruptured* branch points of the avulsed part in order to have a more secure segment for better patency rate.

WHEN? WHICH? WHY?

- Primary Anastomosis with Adequate Bone Shortening?
- Limited Bone Shortening with Vein Grafting?


www.beyzadeoglu.com

Primary Anastomosis with Adequate Bone Shortening?

- Vascular debridement is performed after determining the Ribbon Sign and the Side Branches.
- Release the distal and proximal artery.
- Adequate bone shortening is performed.
- Primary anastomosis is performed if there is no tension at the anastomosis site.
 - **Single anastomosis,**
 - **Single technical risk,**
 - **Shorter surgery time,**
 - **Lower morbidity (no grafting),**
 - **Extensive soft tissue debridement is possible.**

Limited Bone Shortening with Vein Grafting?

- If the injury requires extensive vascular debridement regarding to Ribbon Sign and Side Branches or there are aesthetic and functional drawbacks, limited bone shortening with vein grafting is performed.
 - Extensive vascular resection (especially proximally) is possible.
 - The bone shortening is limited; bone stock is preserved.
 - But double anastomoses bring doubled technical risk and
 - Higher morbidity (grafting).



- Wide distal arterial resection followed by vein grafting has its drawback by not having adequate side branches for soft tissue vascularity, especially at the amputated proximal skin.

To compare the two treatment modalities (Primary Anastomosis and Vein Grafting):

only the cases with avulsion type of **TOTAL** finger amputations were evaluated.

All of the cases were treated according to the principles mentioned before.

- Between 1991 and 2002, replantation of 27 fingers that were totally amputated with avulsion type of injuries were treated.
 - In 15 patients, the injuries were related to heavy manual works.
 - 6 patients had ring injury;
 - 4 patients had fallen from the stairs;
 - 2 had elevator accidents.

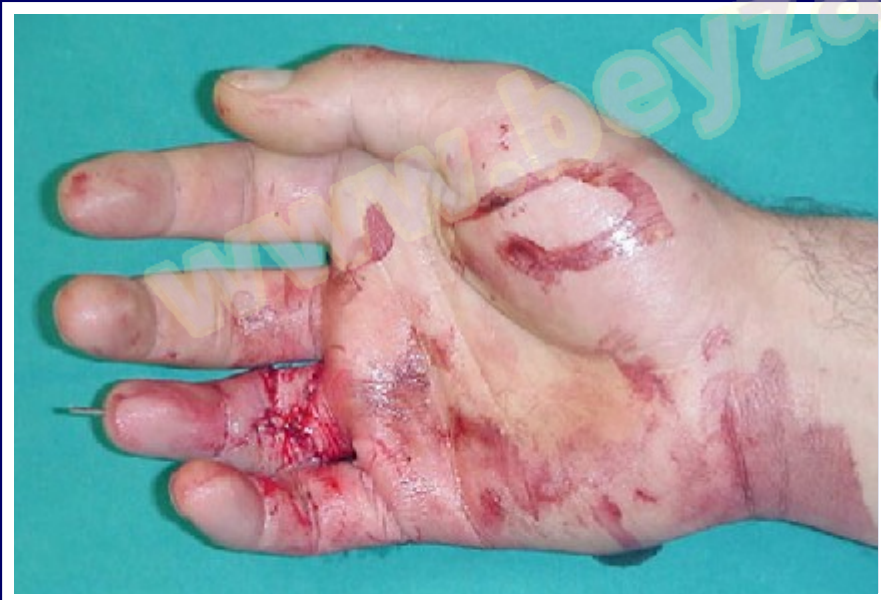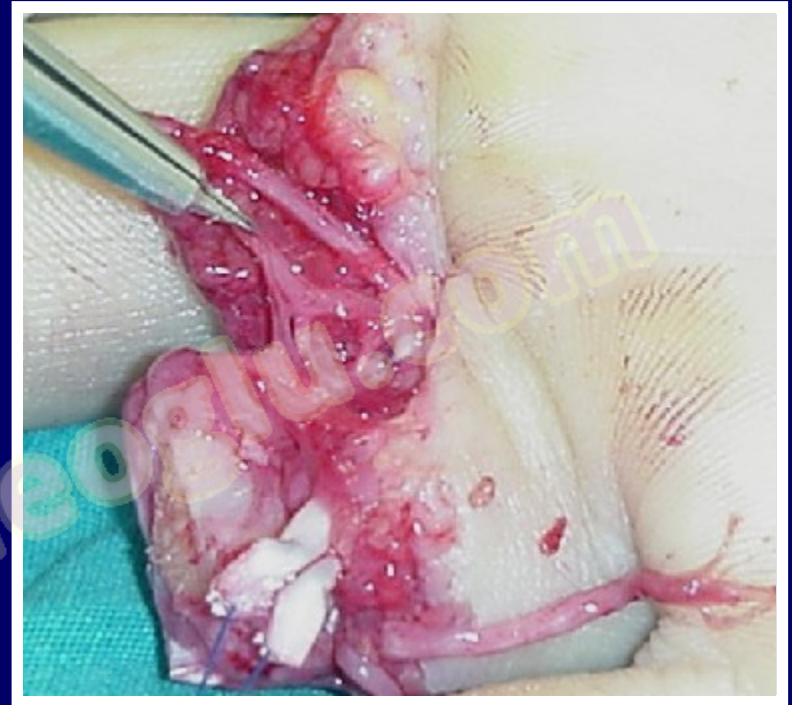
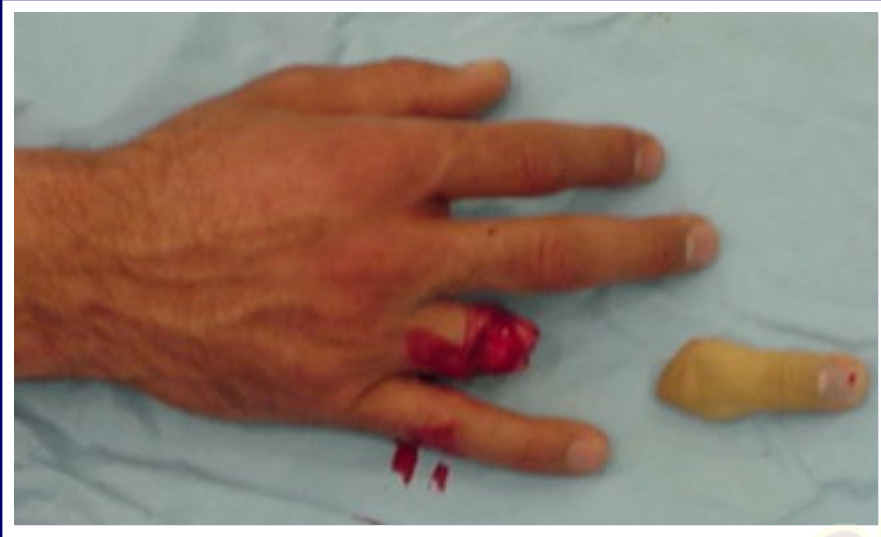27 Total Finger Amputations

- Primary Anastomosis with Adequate Bone Shortening was performed in 20 cases and Failure of replantation occurred in 4 (20%)
- Limited Bone Shortening with Vein Grafting was performed in 7 cases and Failure occurred in 1 case (14.2%).

EXAMPLE CASES

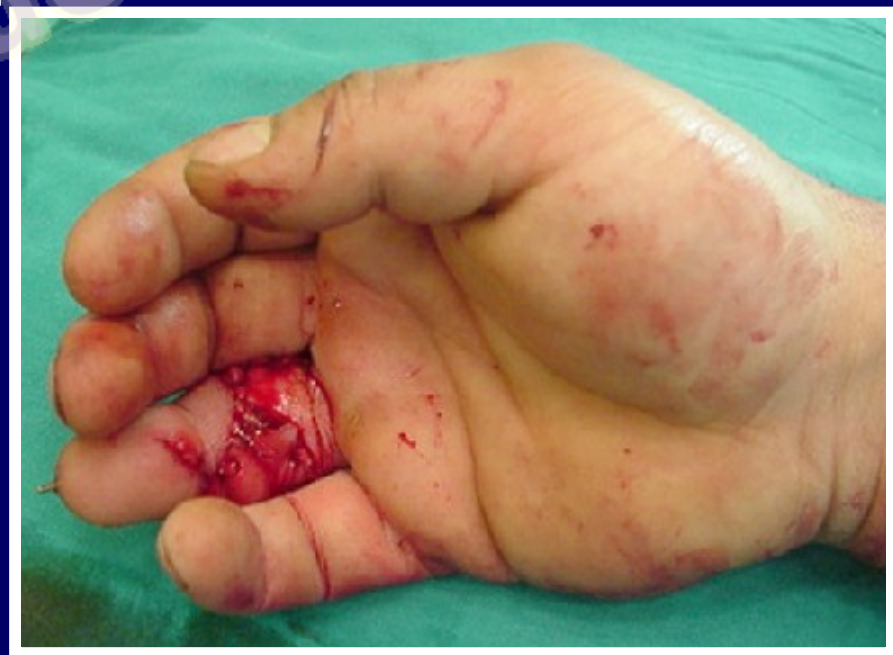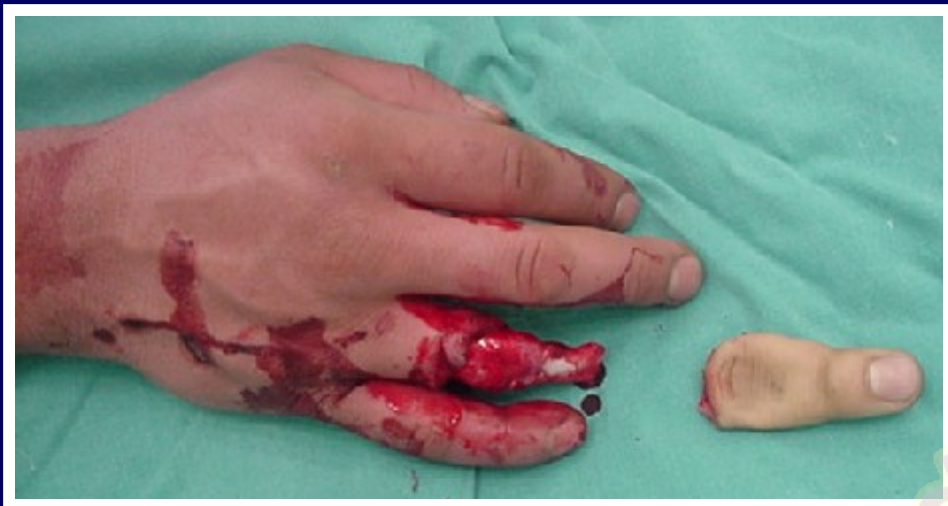www.beyzadeoglu.com

Example for primary anastomosis with adequate bone shortening



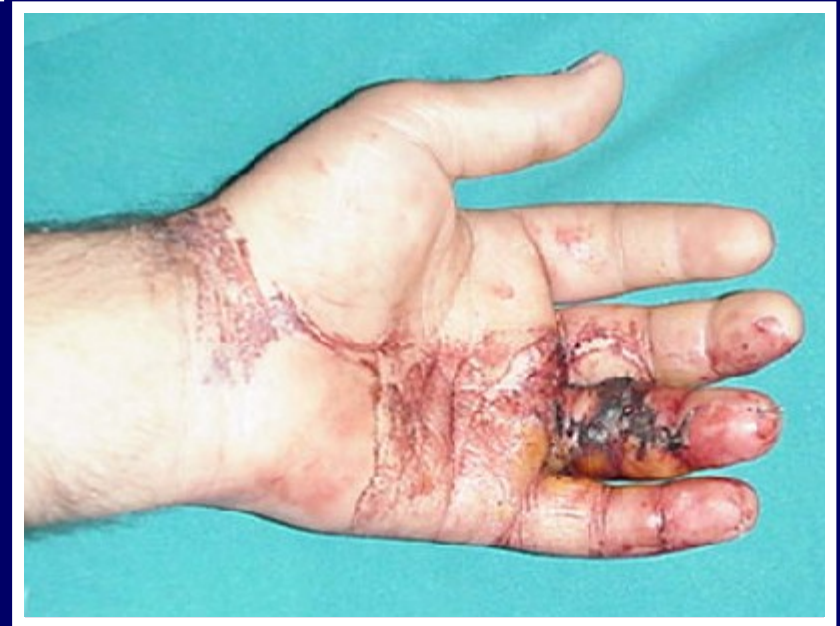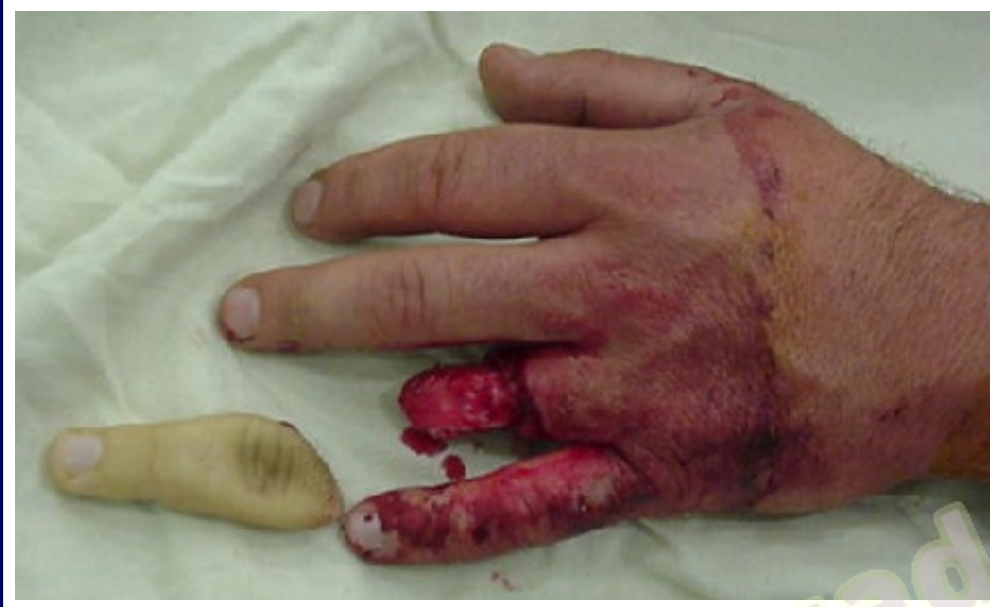Attention to the guidance of the side branches !!!

Example for primary anastomosis with adequate bone shortening



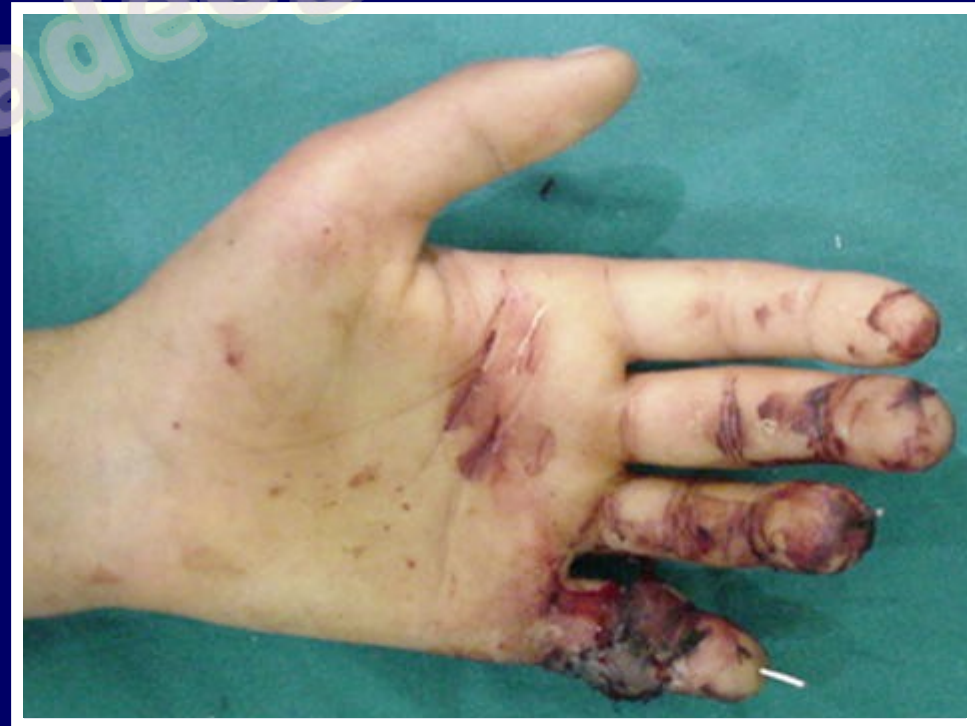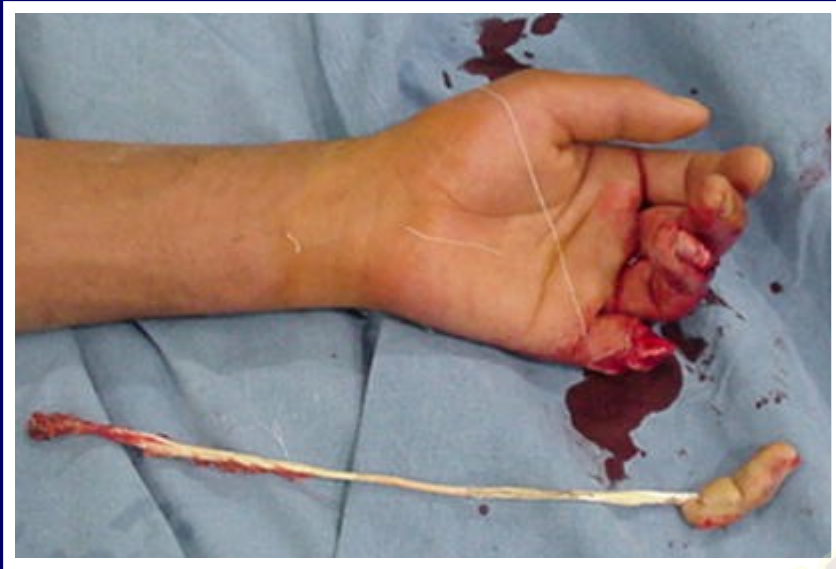www.beyzadeoglu.com

Example for primary anastomosis with adequate bone shortening



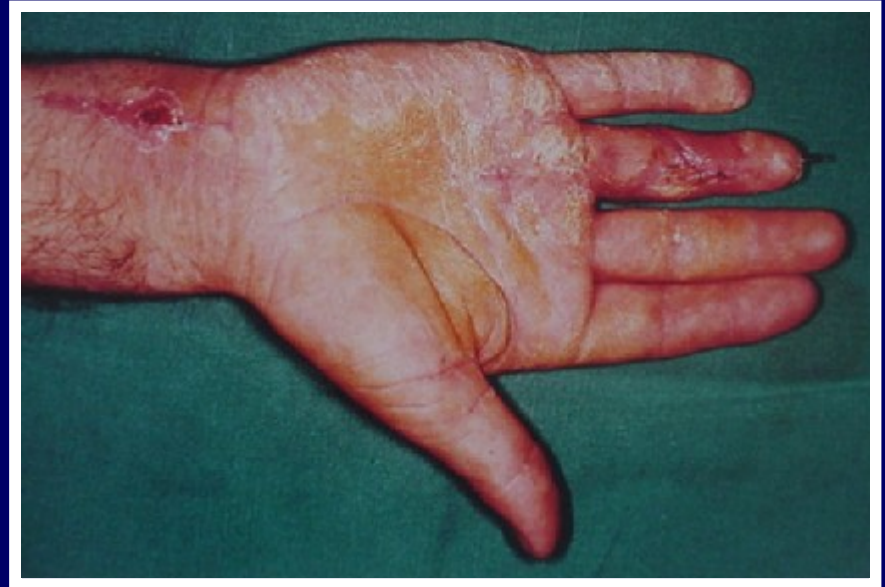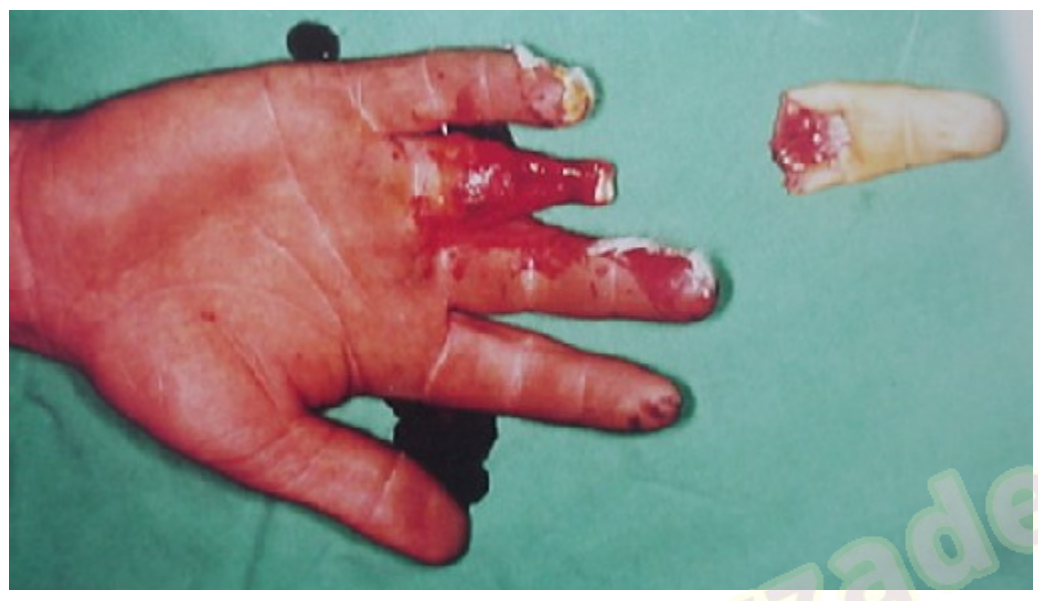www.beyzadeoglu.com

Example for primary anastomosis with adequate bone shortening



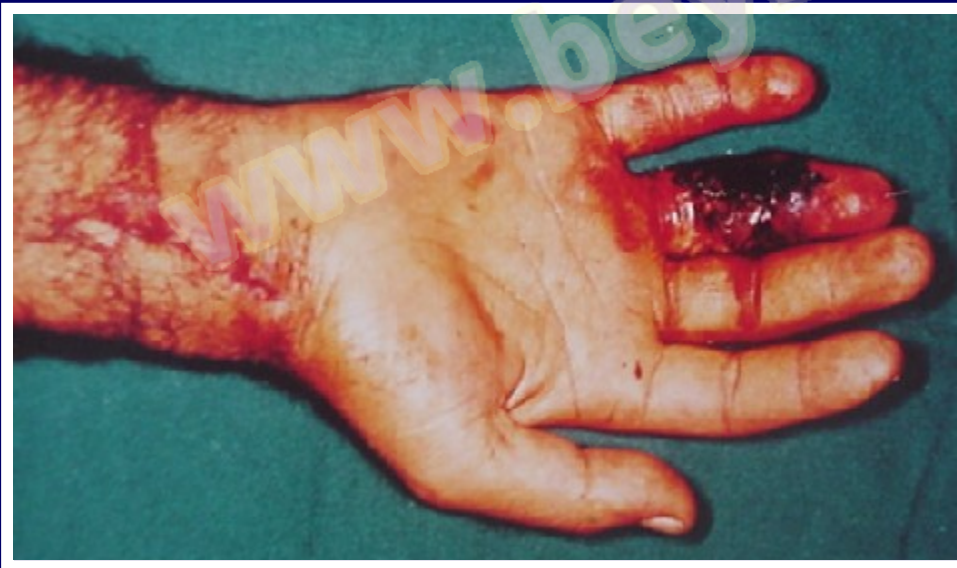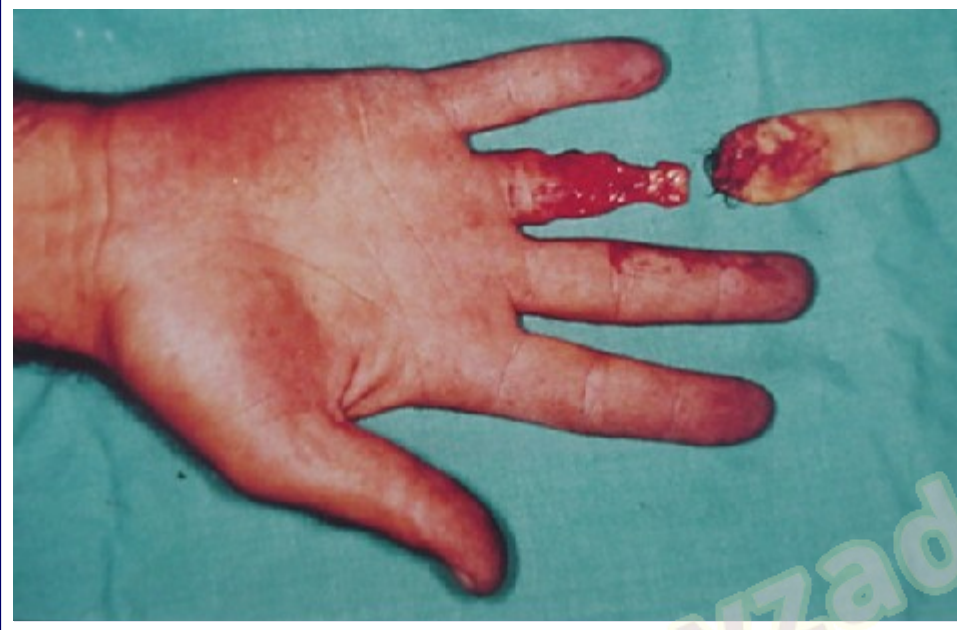www.beyzadeoglu.com

Example for limited bone shortening with vein grafting

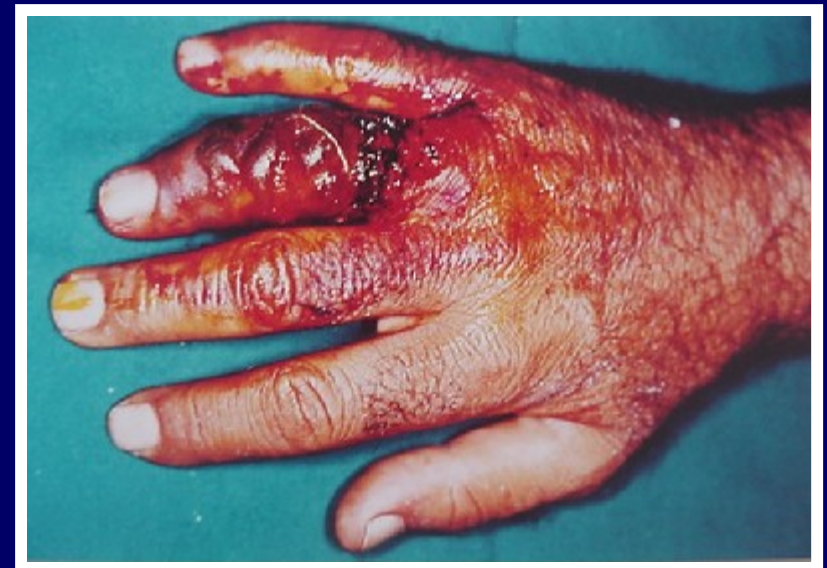

www.beyzadeoglu.com

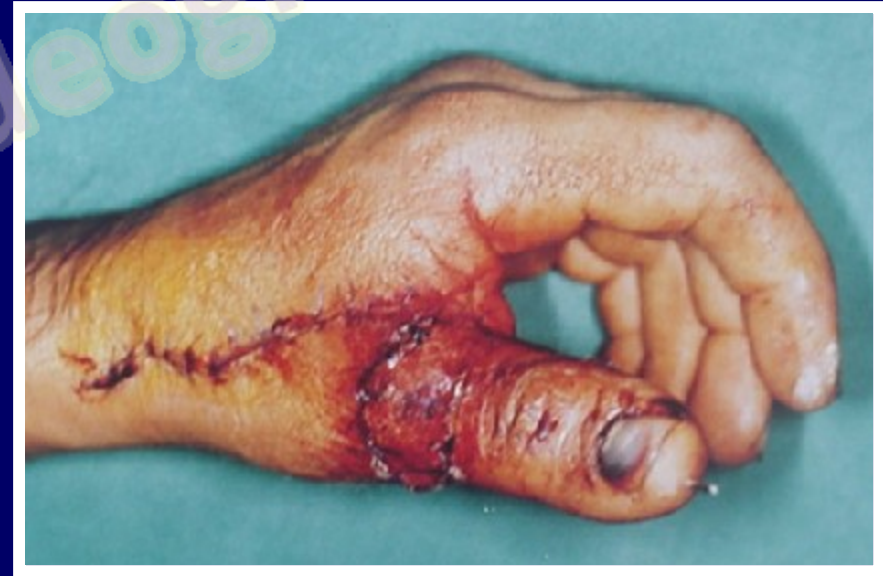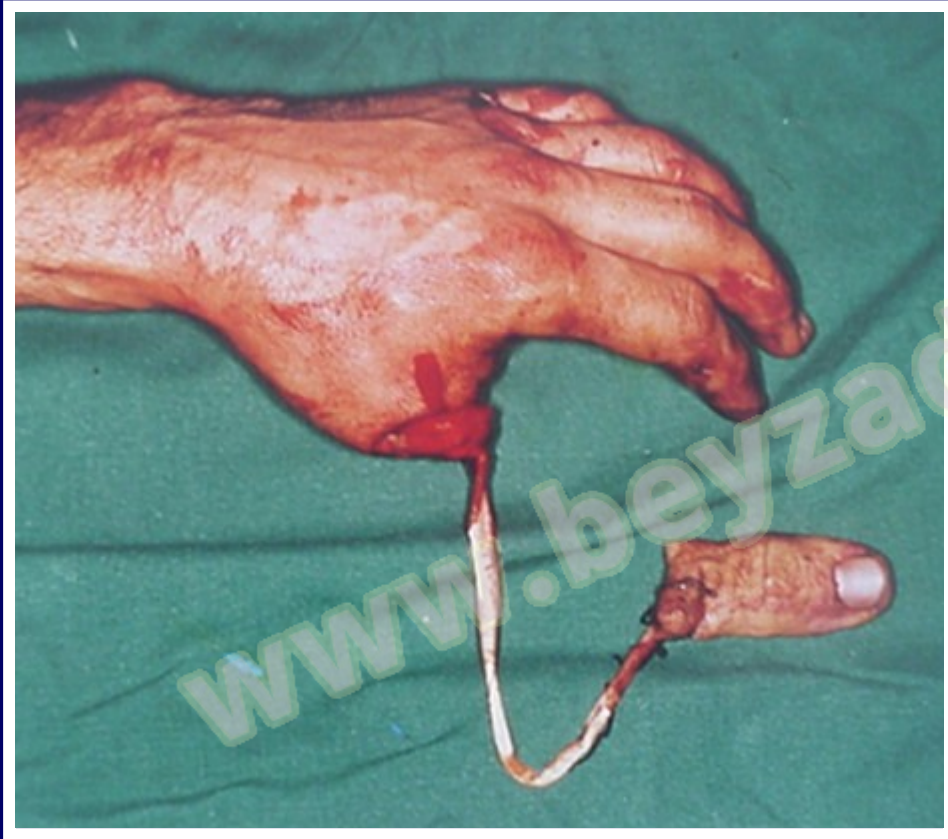Example for limited bone shortening with vein grafting

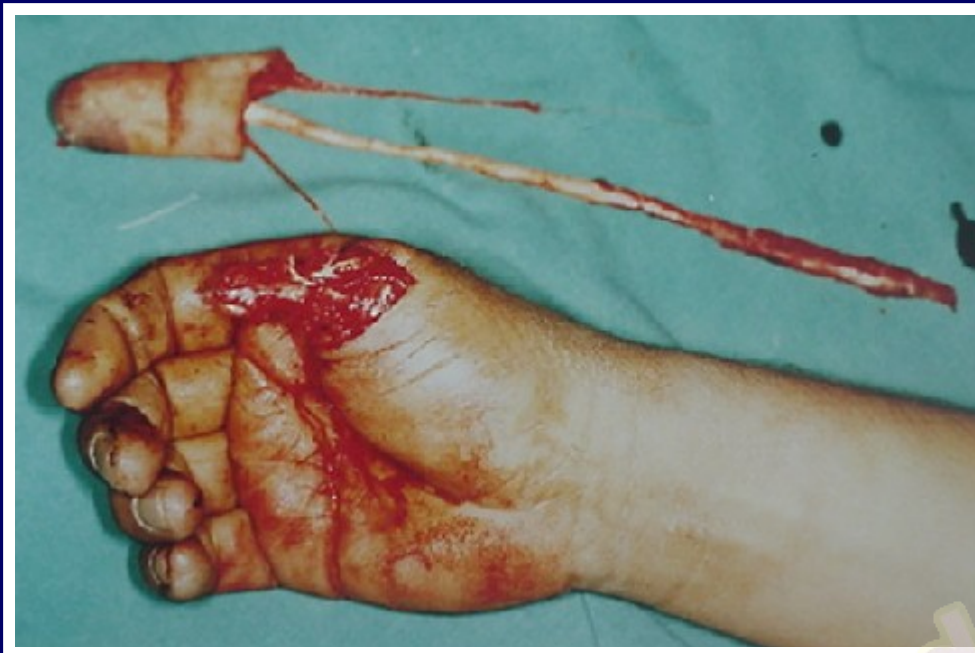

Wide distal arterial resection followed by vein grafting has its drawback by not having adequate side branches for soft tissue vascularity, especially at the amputated proximal skin.

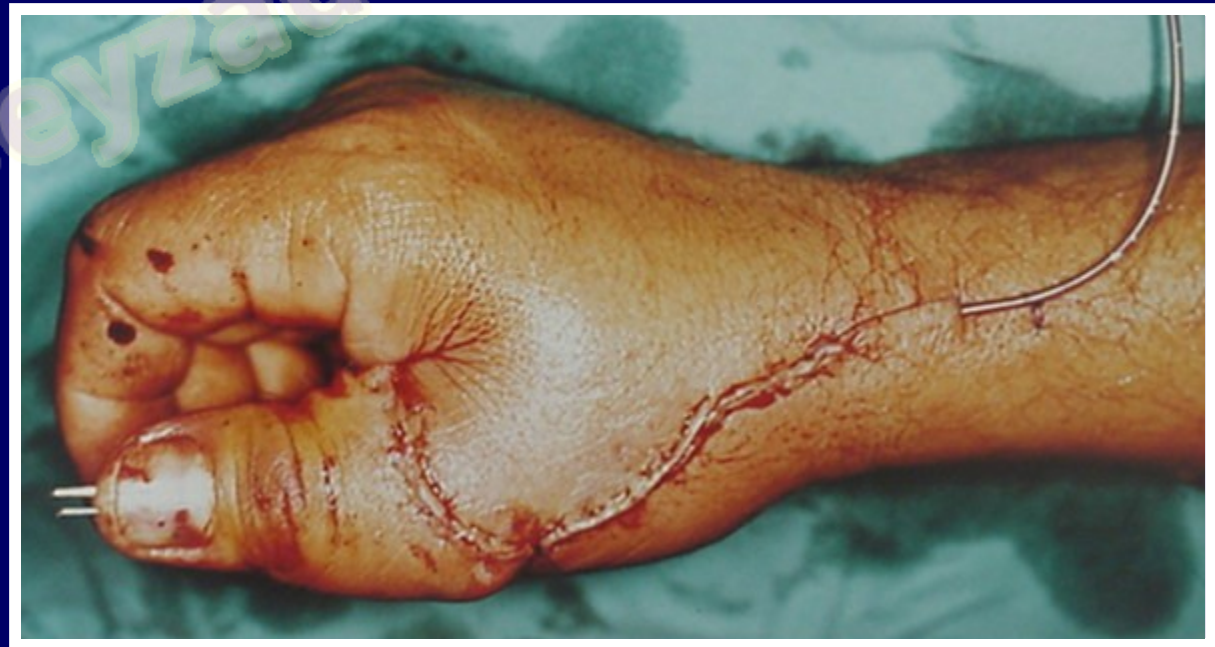

Example for limited bone shortening with vein grafting

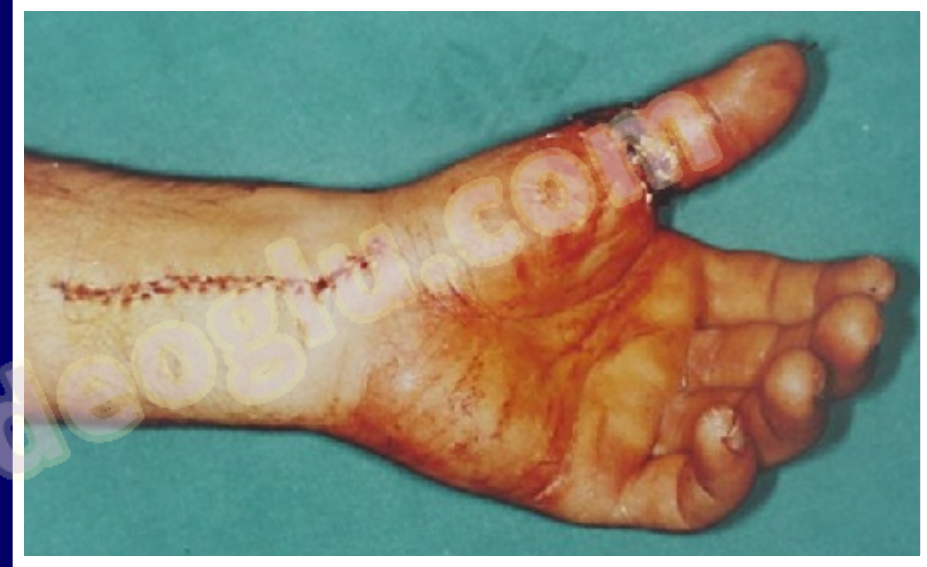
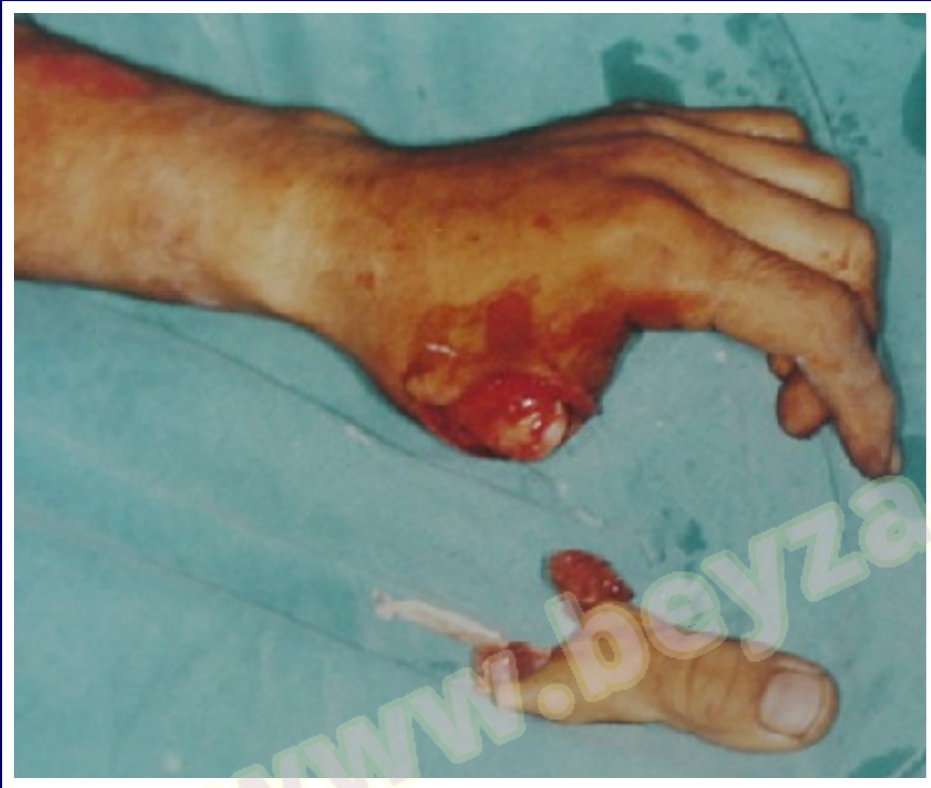


**Example for limited
bone shortening with
vein grafting**



Example for limited bone shortening with vein grafting



www.peyzad.com

CONCLUSION

- Avulsed fingers account the great majority of failed replantations because of the extensive vascular damage that is difficult to determine by an operating microscope. For successful patency rate, suitable vessel should be anastomosed to suitable vessel.
- We prefer to verify the suitable part of the vessel indirectly according to its **Side Branches** and **Ribbon Sign**.

CONCLUSION

- If we are in comfort for the suitable segment of the avulsed artery after limited debridement for anastomosis, we prefer adequate bone shortening with primary anastomosis as a treatment modality.
- If we are not satisfied with the segment of the avulsed artery after limited debridement to be suitable for primary anastomosis in the view of principles above or if the arterial defective gap has to be too wide because of extensive debridement; we prefer limited bone shortening with vein grafting as the treatment modality.

THANK YOU

www.beyzadeoglu.com